Fraser Health Long Term Care Rounds

Arthritis: Is this Rheumatoid?

Lucy Chu

Oct 2022

CONTENTS

1. Background
2. Manifestations
3. Diagnostic Work Up
4. Management
5. Prognosis
6. Bone Health

DISCLOSURES

I do not have an affiliation (financial or otherwise) with any for-profit or not-for-profit organizations

LEARNING OBJECTIVES

1. Identify distinguishing features for inflammatory arthritis
2. Differentiate x-ray findings in inflammatory vs degenerative arthritis
3. Provide monitoring of DMARD therapy if patient is lost to rheum follow up
4. Develop an approach to tapering or stopping medications for patients in remission

BACKGROUND

EPIDEMIOLOGY

- Prevalence ~ 1%
- 2-3 F:M 1
- Age: Bimodal - child-bearing age, perimenopausal

- Ethnic variability:
  - 5 % First Nations (Pima, Algonquin and Chippewa)
  - 1% Northern Europeans
  - 0.3% Han Chinese
  - 0.1 % rural Africans

RISK FACTORS

- Likely multifactorial

- Genetic risk factors (60%)
  - HLA DRB1
  - Epigenetic modifications - acetylation, citrullination, carbamylation

- Non-genetic risk factors (40%)
  - Smoking
  - Female sex
  - Vitamin D deficiency
  - Microbiome
    - *P. gingivalis*, common in periodontal disease, expresses peptidyl arginine deiminases → induce citrullination
    - *A. actinomycetemcomitans*, produces a toxin that increases calcium influx into neutrophils → neutrophils release peptidyl arginine deiminase → induce citrullination

CITRULLINATION

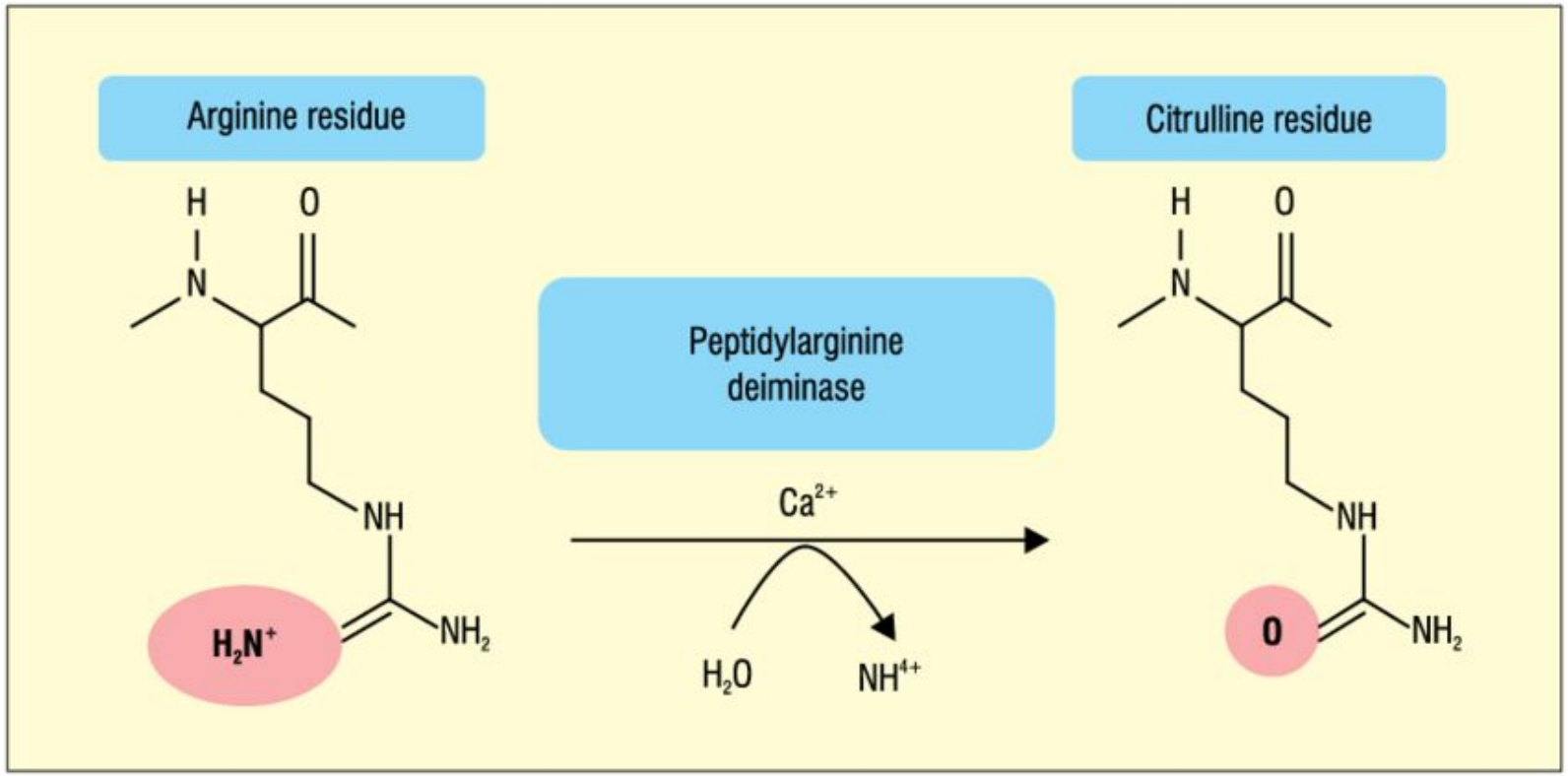

CITRULLINATION

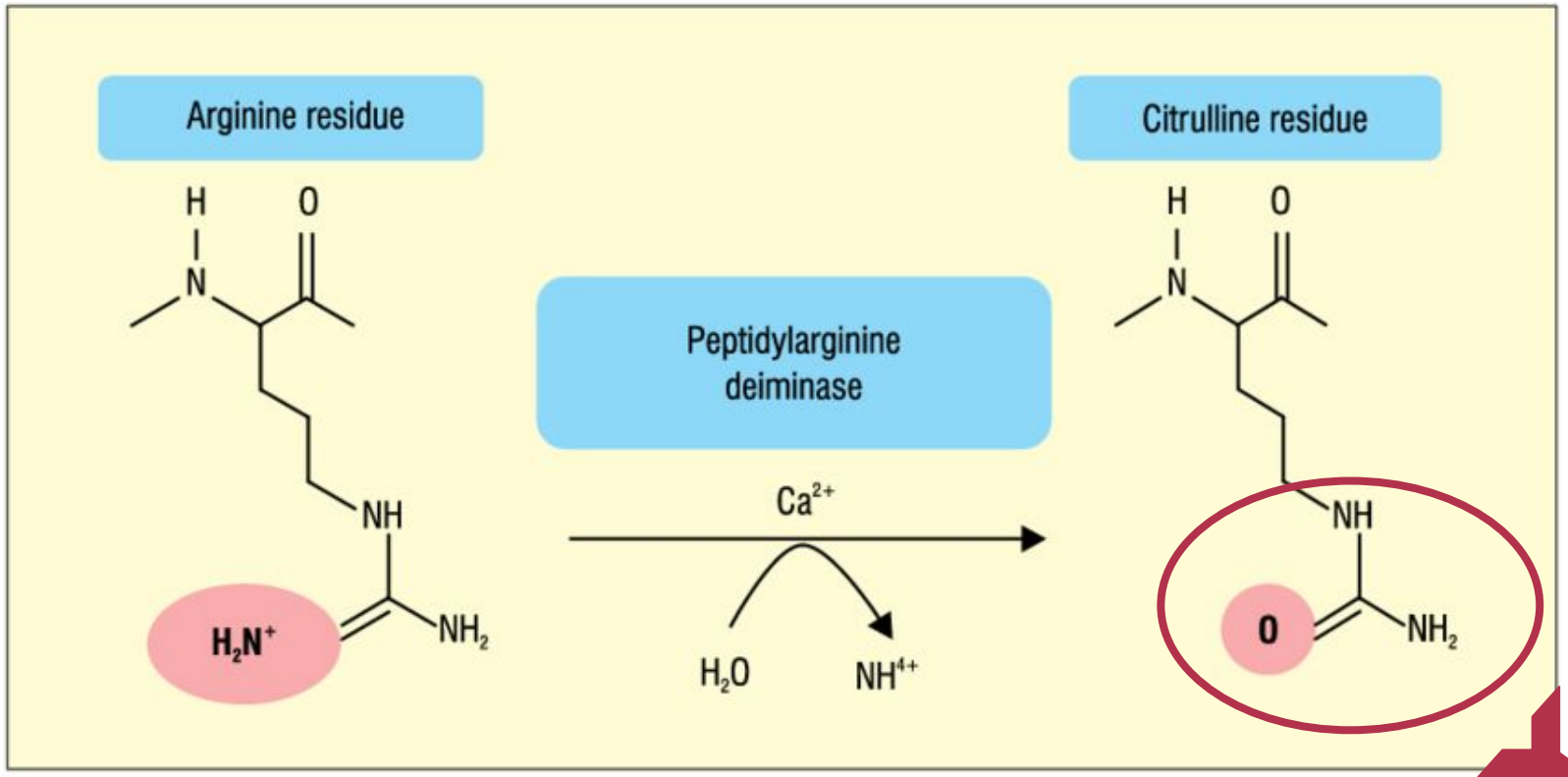

PATHOPHYSIOLOGY

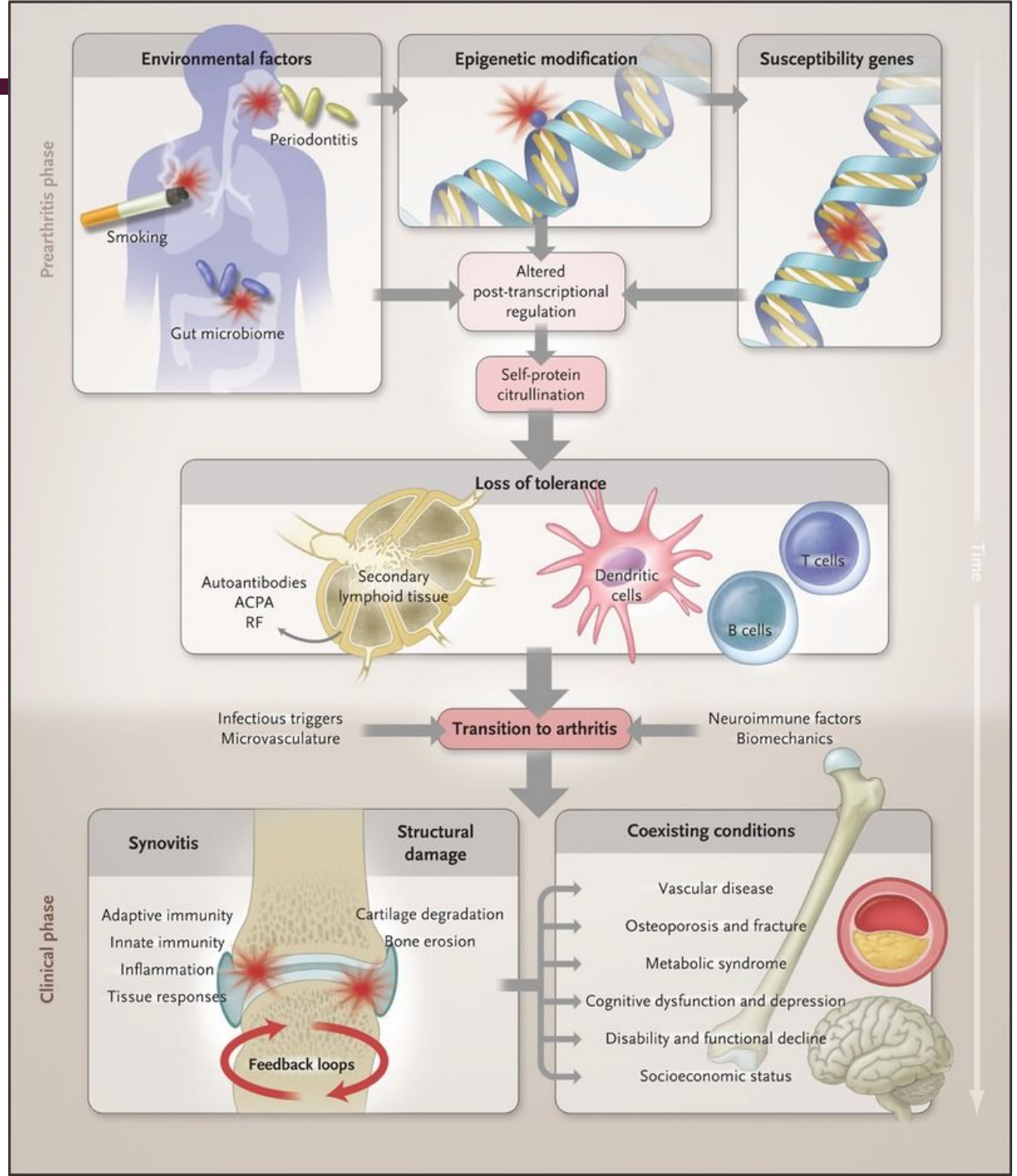

TIMELINE

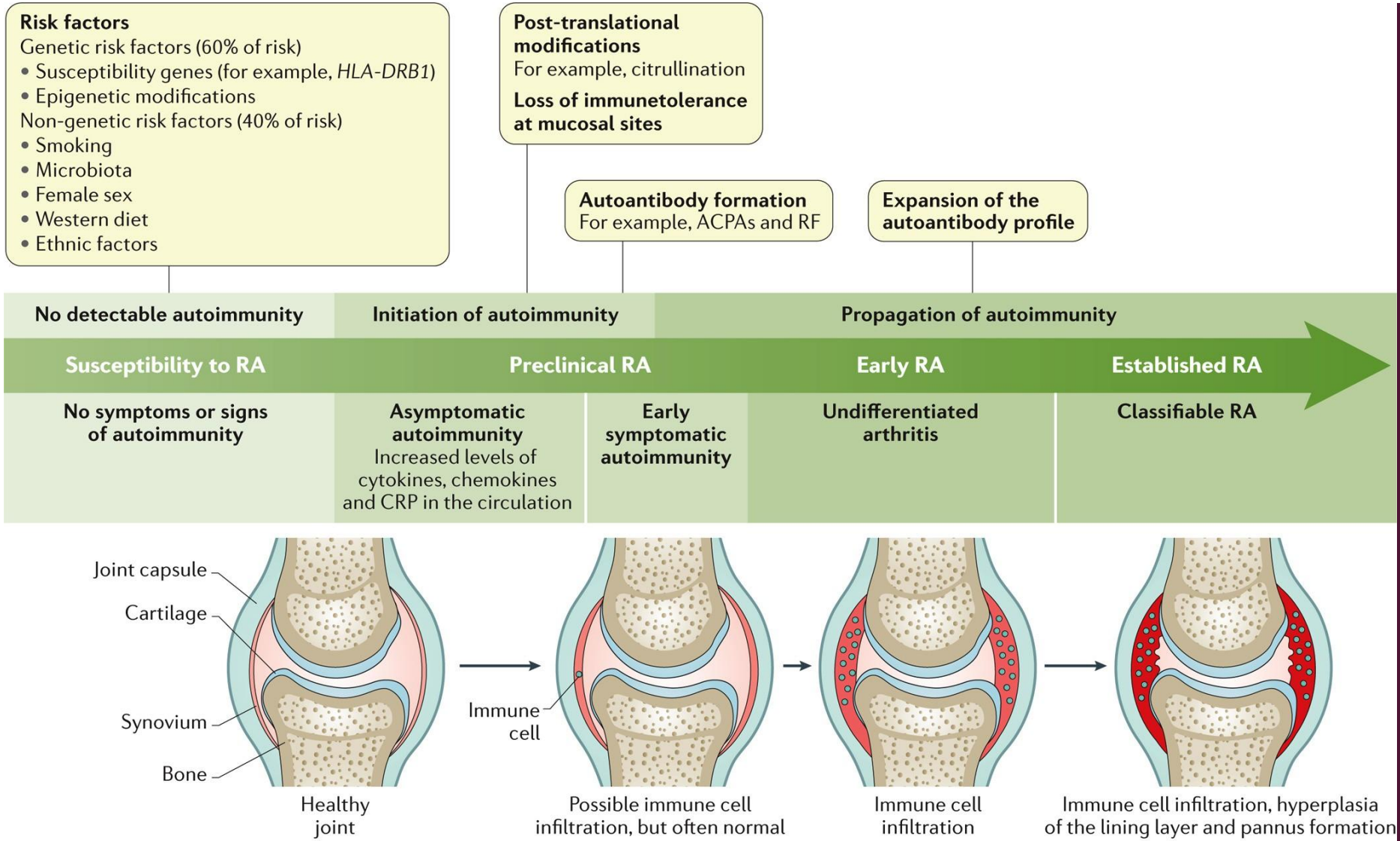
Risk factors
Genetic risk factors (60% of risk)
• Susceptibility genes (for example, HLA-DRB1)
• Epigenetic modifications
Non-genetic risk factors (40% of risk)
• Smoking
• Microbiota
• Female sex
• Western diet
• Ethnic factors
Post-translational modifications
For example, citrullination
Loss of immunetolerance at mucosal sites
Autoantibody formation
For example, ACPAs and RF
Expansion of the autoantibody profile
No detectable autoimmunity
Initiation of autoimmunity
Propagation of autoimmunity
Susceptibility to RA
Preclinical RA
Early RA
Established RA
No symptoms or signs of autoimmunity
Asymptomatic autoimmunity
Increased levels of cytokines, chemokines and CRP in the circulation
Early symptomatic autoimmunity
Undifferentiated arthritis
Classifiable RA
Joint capsule
Cartilage
Synovium
Bone
Immune cell
Healthy joint
Possible immune cell infiltration, but often normal
Immune cell infiltration
Immune cell infiltration, hyperplasia of the lining layer and pannus formation

MANIFESTATIONS

CASE 1: Jane Payne

50 year old otherwise healthy female

- New migratory joint pain up to 6/10 affecting wrists, PIPs, knees and ankles for the past 2 months
- Morning stiffness lasts approximately 30 minutes, better after a shower in the morning
- Denies any obvious swelling
- Review of systems unremarkable
- Today is a "good" day, exam does not reveal joint tenderness or swelling
- RF, CCP, ANA negative
- X-rays reveal osteophytes and joint space narrowing

INFLAMMATORY OR NOT?

CASE 1: Jane Payne

50 year old otherwise healthy female

- New migratory joint pain up to 6/10 affecting wrists, PIPs, knees and ankles for the past 2 months
- Morning stiffness lasts approximately 30 minutes, better after a shower in the morning
- Denies any obvious swelling
- Review of systems unremarkable
- Today is a "good" day, exam does not reveal joint tenderness or swelling
- RF, CCP, ANA negative
- X-rays reveal osteophytes and joint space narrowing

INFLAMMATORY OR NOT?

Yes, distribution is key! Involvement of elbows, wrists, MCPs, and ankles is concerning inflammatory.

JOINT DISTRIBUTION

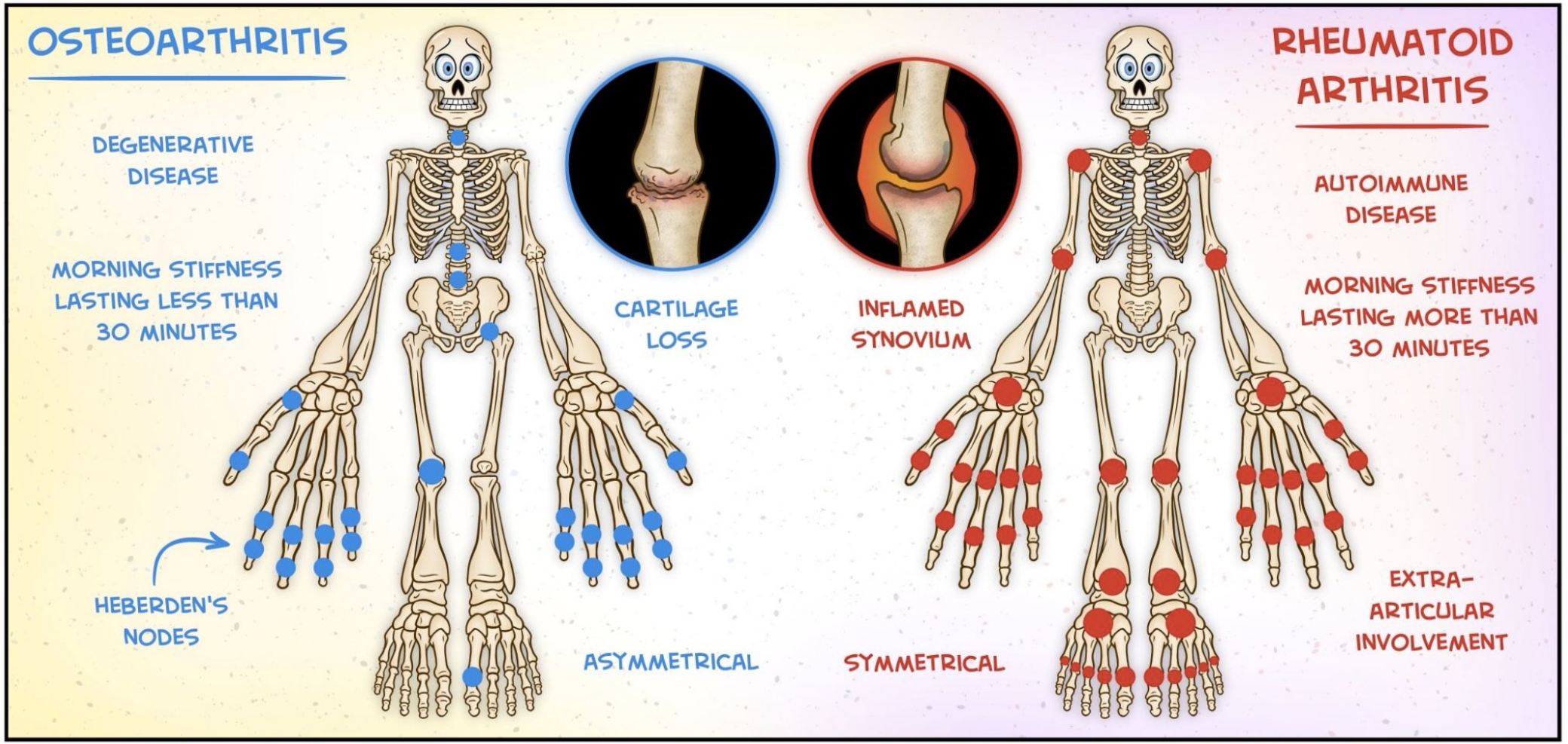

INFLAMMATORY VS DEGENERATIVE

RHEUMATOID ARTHRITIS

- Autoimmune
- Morning stiffness > 30 minutes
- Improves with activity
- Better in the evening
- Symmetric
- Neck pain
- Rheumatoid nodules
- Elevated inflammatory markers
- Multi-organ involvement
- Joint swelling
- Relapsing, remitting course

OSTEOARTHRITIS

- "Wear and tear"
- Morning stiffness < 30 minutes
- Improves with rest
- Worse in the evening
- Asymmetric
- Lower back, neck pain
- Ganglion cysts
- Normal inflammatory markers
- Not systemic
- Osteophytes
- Slowly, progressive course

MANIFESTATIONS

ARTICULAR:

- Radial deviation at wrists
- Ulnar deviation/subbluxation at MCPs
- Z-deformity of thumbs
- Boutonniere deformity
- Swan neck deformity
- Cervical (C1/C2) instability

EXTRA-ARTICULAR:

- Eyes: episcleritis, scleritis
- Heart: pericardial effusion
- Lungs: interstitial lung disease
- Skin: rheumatoid nodules, livedo reticularis

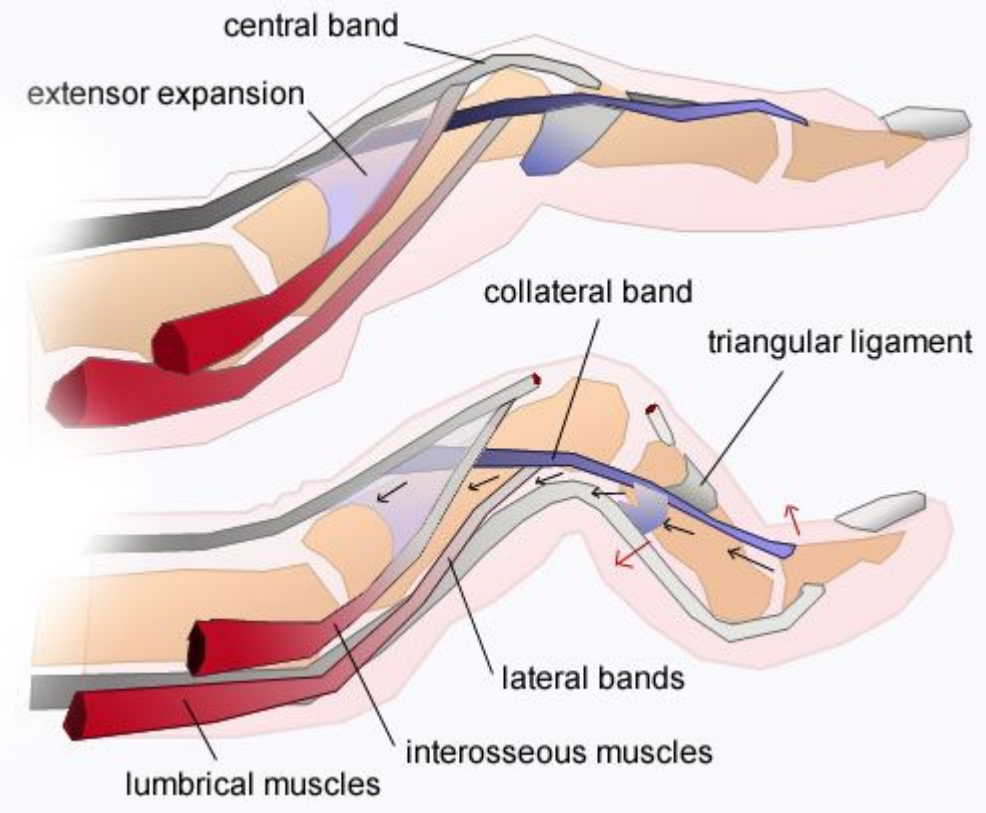

MANIFESTATIONS

FELTY SYNDROME:

- rheumatoid arthritis
- leukopenia/neutropenia
- splenomegaly

CAPLAN SYNDROME:

- rheumatoid arthritis
- pneumoconiosis

DIAGNOSTIC WORK UP

CLASSIFICATION CRITERIA =/= DIAGNOSTIC CRITERIA

2010 ACR/EULAR Criteria for RA Diagnosis		
A.	**Joint involvement**	
	1 large joint	0
	2-10 large joints	1
	1-3 small joints	2
	4-10 small joints	3
	>10 joints (≥1 small joint)	5
B.	**Serology (≥1 test result needed)**	
	Negative RF and negative ACPA	0
	Low-positive RF or low-positive ACPA	2
	High-positive RF or high-positive ACPA	3
C.	**Acute-phase reactants (≥1 test result needed)**	
	Normal CRP and normal ESR	0
	Abnormal CRP or abnormal ESR	1
D.	**Duration of symptoms**	
	<6 wk	0
	≥6 wk	1
Definite diagnosis requires total score ≥6/10.		

BLOODWORK

- HISTORY/PHYSICAL
  - as discussed
- BLOODWORK
  - CBC, Cr, LFT
  - Markers of inflammation → CRP, ESR, ferritin, SPEP
  - Rheumatoid factor, anti-CCP *15% will be seronegative
  - (TSH, uric acid, ANCA, HLA B27 for differential diagnosis)
  - HIV, Hep B, Hep C
- IMAGING
  - Xrays
  - Ultrasound

X-Ray Series



Rheumatoid Arthritis Hand

- Loss of intercarpal, carpometacarpal and distal radio-ulnar joint spaces
- Ulnar deviation of MCP joints
- Yellow arrows indicate Boutonierre deformity
- Red arrow indicates hitch-hiker thumb deformity
- Red circle indicates key area of affection of the intercarpal spaces

For Education & Awareness Purpose Only

X-RAY



X-RAY





CASE 2: Gully Hicks

80 year old male with diabetes, CKD

- Retired carpenter with longstanding pain in his hands getting progressively worse
- Mild swelling of a few PIP and DIP and CMC joints
- X-ray report describes central erosions at the PIP and DIP joints

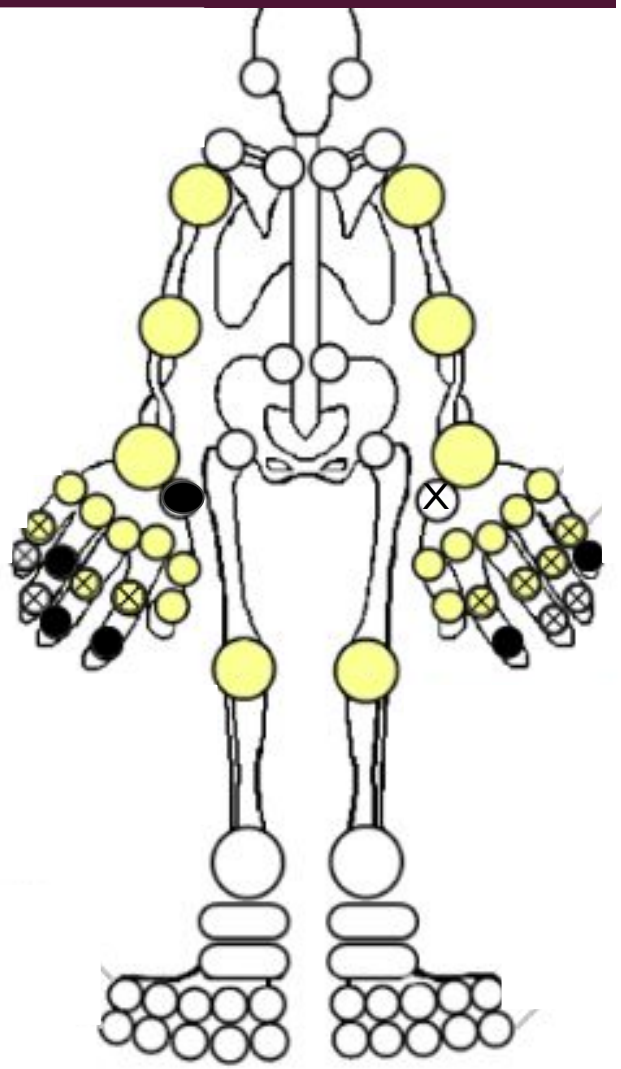

CASE 2: Gully Hicks

80 year old male with diabetes, CKD

- Retired carpenter with longstanding pain in his hands getting progressively worse
- Mild swelling of a few PIP and DIP and CMC joints
- X-ray report describes central erosions at the PIP and DIP jo

WHAT IS THE DIAGNOSIS?



CASE 2: Gully Hicks

70 year old male with diabetes

- Retired carpenter with longstanding pain in his hands getting progressively worse
- Mild swelling of a few PIP and DIP and CMC joints
- X-ray report describes central erosions at the PIP and DIP jo

WHAT IS THE DIAGNOSIS?

Erosive/inflammatory osteoarthritis - not considered a true inflammatory condition
Characteristic gull wing or inverted T erosions



EROSIVE OSTEOARTHRITIS

- osteophytes
- central "erosions"
- hallmark "gull wing"
- "inverted T" appearance

(not autoimmune or synovial based)



EROSIVE OSTEOARTHRITIS

- Aggressive subset (5% to 10%) of primary osteoarthritis
- Involves the DIP joints, PIP joints, and first CMC joints
- There is a component of joint inflammation that is superimposed on the degenerative osteoarthritic symptoms
- Usually waxes and wanes for up to 5 years with painful flares leading to joint deformities
- Unlike RA, it is not accompanied by systemic symptoms or autoimmune serology
- X-rays: osteophytes, central "erosions" with a hallmark "gull wing" or "inverted T" appearance → not synovial based
- Centrally eroded cartilage is not caused by synovial pannus invasion
    - possibly due to matrix metalloproteinases leading to cartilage destruction or a role of CPPD crystals
- Treatment: NSAID, steroid injection
    - Hydroxychloroquine used off-label with varying success

MANAGEMENT

MANAGEMENT

ACR 2015 Treatment Guidelines

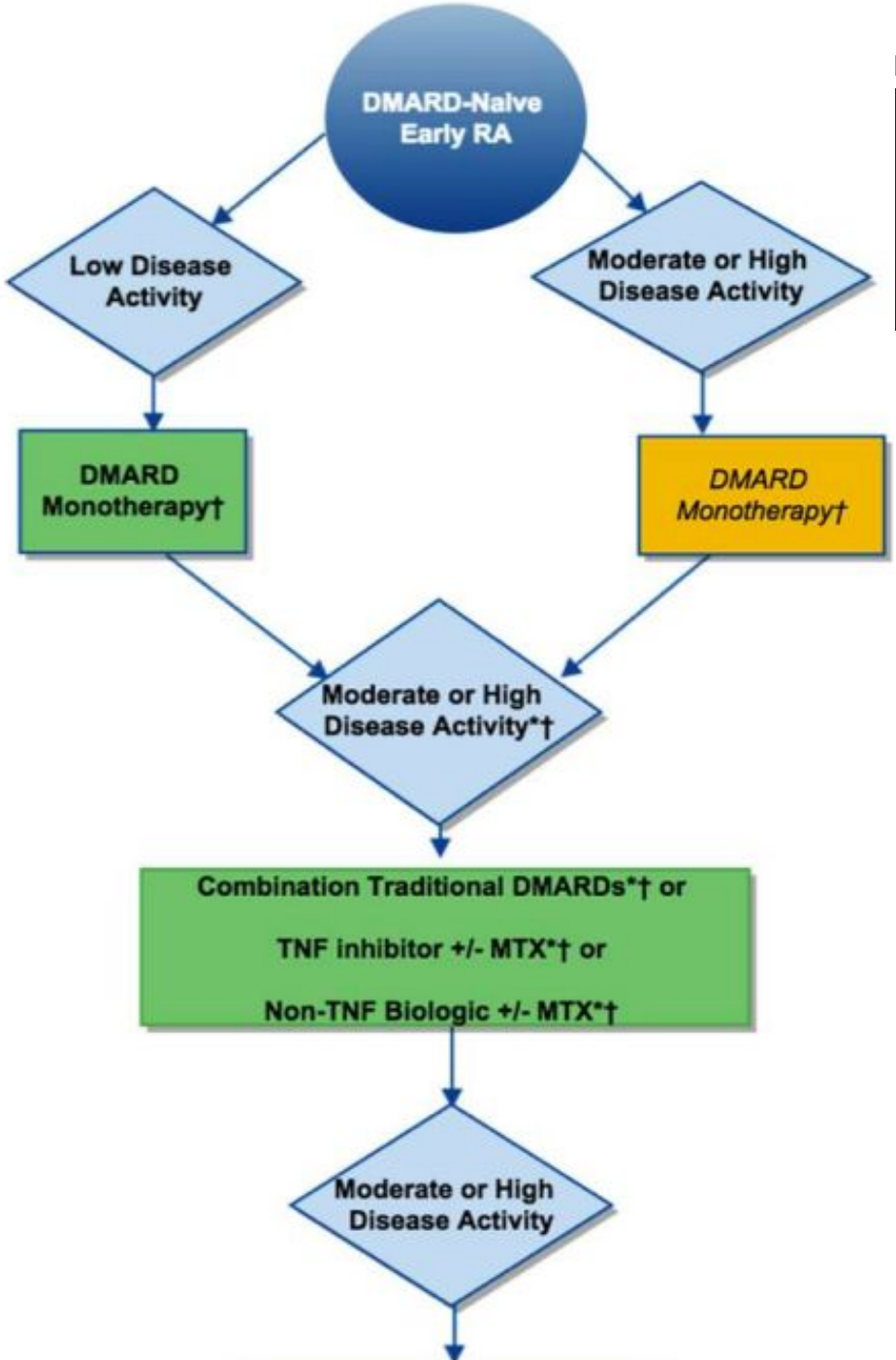

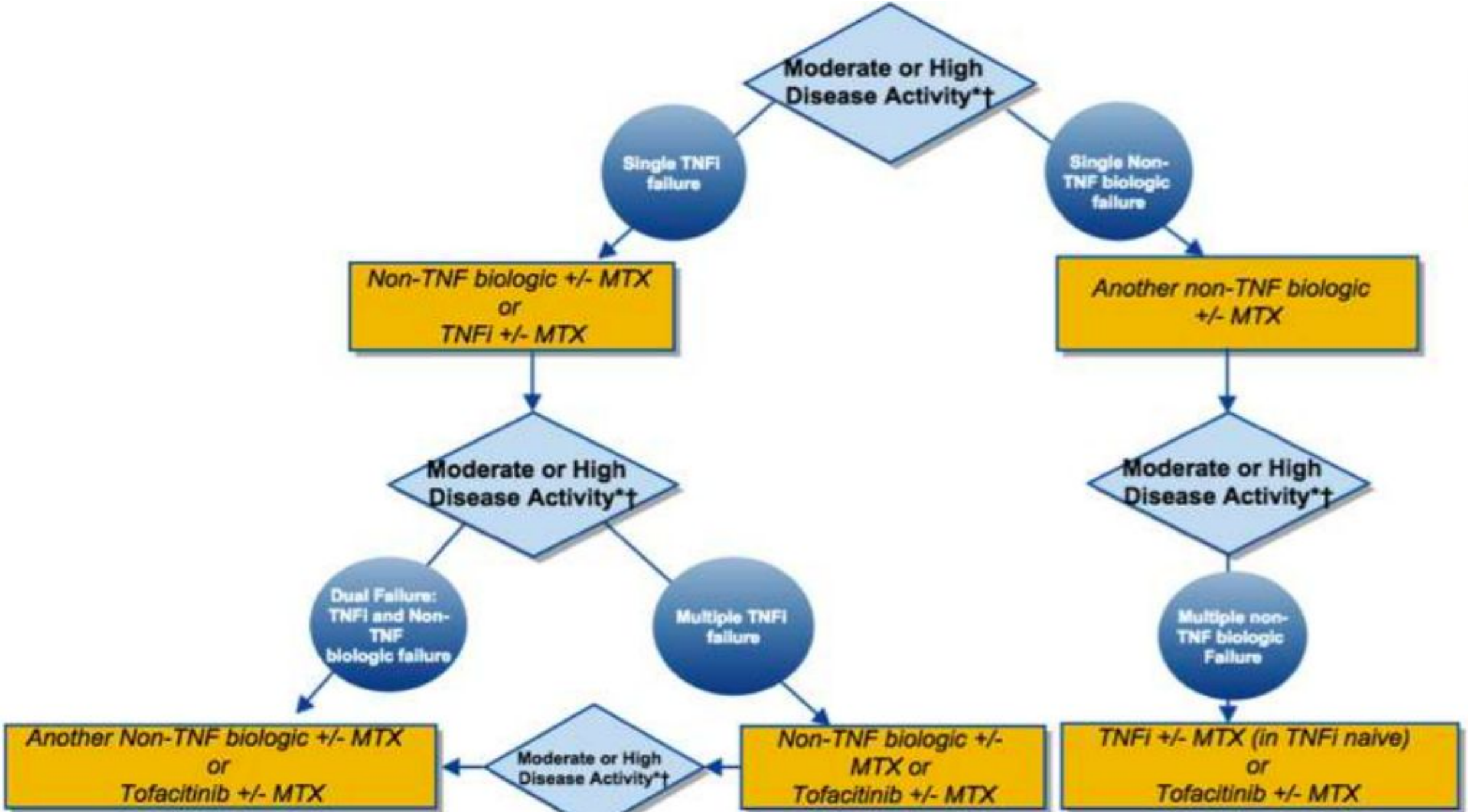
Moderate or High Disease Activity*†
Single TNFi failure
Single Non-TNF biologic failure
Non-TNF biologic +/- MTX or TNFi +/- MTX
Another non-TNF biologic +/- MTX
Moderate or High Disease Activity*†
Moderate or High Disease Activity*†
Dual Failure: TNFi and Non-TNF biologic failure
Multiple TNFi failure
Multiple non-TNF biologic Failure
Another Non-TNF biologic +/- MTX or Tofacitinib +/- MTX
Moderate or High Disease Activity*†
Non-TNF biologic +/- MTX or Tofacitinib +/- MTX
TNFi +/- MTX (in TNFi naive) or Tofacitinib +/- MTX

METHOTREXATE

METHOTREXATE

- Drug of choice
- Slow onset of action (8-12 weeks) therefore may need to temporize with prednisone
- Mechanism
  - inhibits dihydrofolate reductase → reduces T cell production
- Adverse effects
  - common: nausea, fatigue, brain fog, hair loss, oral ulcers
  - serious: teratogenic, liver injury, leukopenia, interstitial lung disease
- Prescribe folic acid 1 mg daily (except day of methotrexate) to prevent adverse effects

OTHER DMARDs

LEFLUNOMIDE

- Teratogenic → cholestyramine washout OR wait 2 years
- Similar to methotrexate (overlapping pathways)
- Risk of peripheral neuropathy and hypertension

SULFASALAZINE

- Safe in pregnancy
- Avoid in sulfa allergy
- Risk of photosensitivity

HYDROXYCHLOROQUINE

- Safe in pregnancy
- Well tolerated
- Risk of retinal toxicity → weight based dosing of 5 mg/kg (maximum 400 mg per day)

DMARD MONITORING

METHOTREXATE

- Monitor CBC, creatinine, ALT, AST, CRP every 3 months.

SULFASALAZINE

- Monitor CBC, creatinine, ALT, AST, CRP every 3 months.

LEFLUNOMIDE

- Monitor CBC, creatinine, ALT, AST, CRP every 3 months.

HYDROXYCHLOROQUINE

- Annual eye exam to rule out retinal toxicity

BIOLOGIC TARGETS

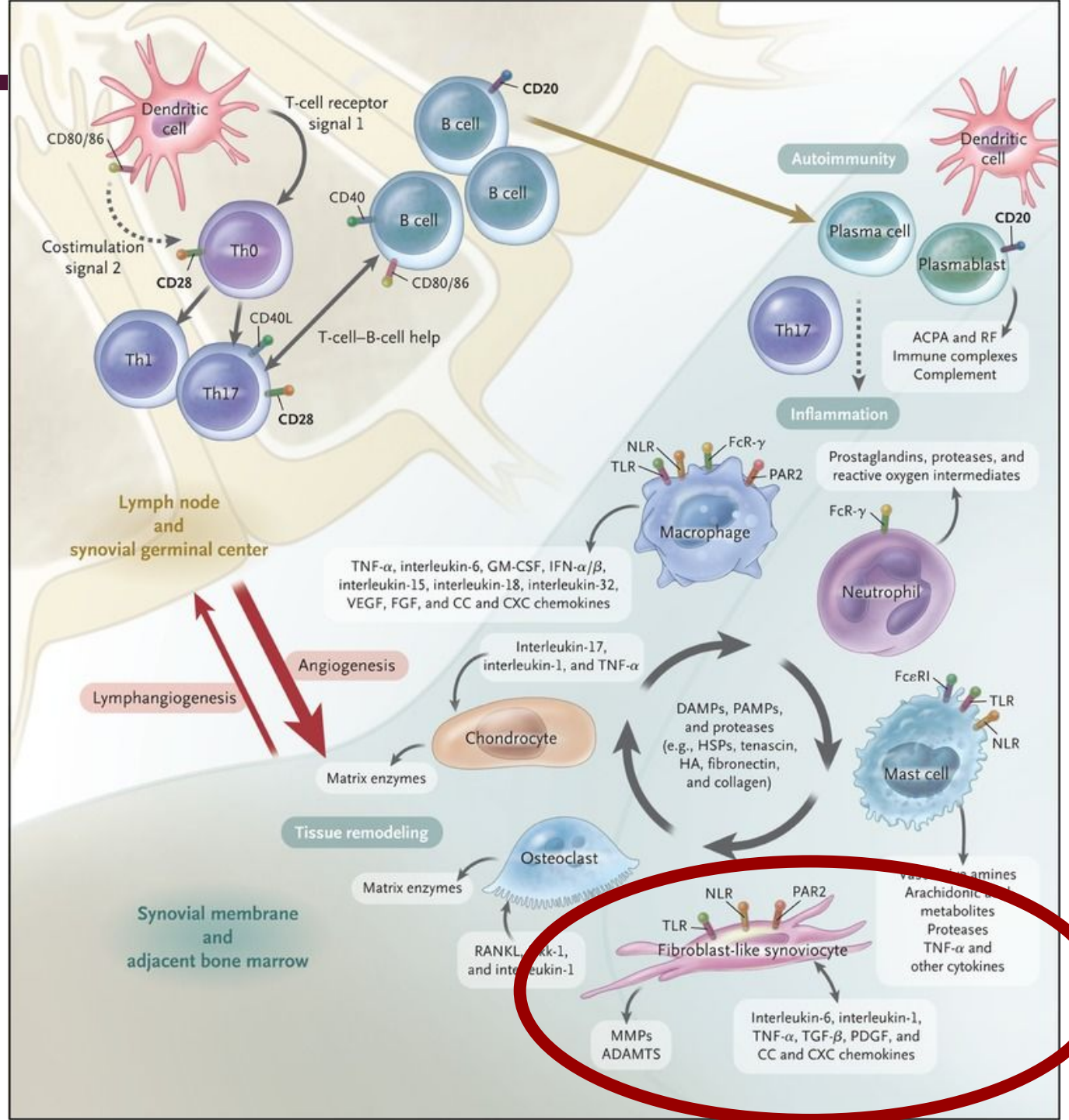

BIOLOGICS IN RHEUMATOID ARTHRITIS

Mechanism	Examples
TNF inhibitors	etanercept, infliximab, adalimumab, golimumab, certolizumab
IL-1 inhibitors	abakinra, canakinumab
IL-6 inhibitors	tocilizumab, sarilumab
CTLA4-Ig	abatacept
B-cell depletion	rituximab, belimumab
JAK inhibitors	tofacitinib, baricitinib, upadactinib

BIOLOGICS IN RHEUMATOID ARTHRITIS

Mechanism	Adverse Effects
TNF inhibitors	May cause drug-induced SLE or MS May worsen CHF
IL-1 inhibitors	Hepatitis: ranges from elevated liver enzymes to hepatocellular necrosis (generally reversible)
IL-6 inhibitors	Raises lipid levels May increase risk of diverticulitis/bowel perforation
CTLA4-Ig	May exacerbate COPD
B-cell depletion	Highest risk of hepatitis B reactivation Monitor for hypogammaglobulinemia prior to each dose Rarely associated with PML (JC virus)
JAK inhibitors	May increase risk of diverticulitis/bowel perforation FDA black box: increased risk of serious CV events, cancer, thrombosis compared to TNFi

PROGNOSIS

MONITORING DISEASE ACTIVITY

- Duration of morning stiffness <30 minutes
- HAQ score (see next slide)
- Swollen joint count
- ESR, CRP
- Repeat x-rays every 1-2 years to assess for new erosions
- Ultrasound of hands to assess for active synovitis/tenosynovitis (more widely available in Ontario)
- In patients with longstanding disease, activity tends to decrease with advanced age

- Tools: DAS28, CDAI, SDAI, RAPID3, etc

HEALTH ASSESSMENT QUESTIONNAIRE

1. Please check (✓) the ONE best answer for your abilities <u>at this time</u>:

AT THIS MOMENT, are you able to,	Without **ANY** Difficulty	With **SOME** Difficulty	With **MUCH** Difficulty	**UNABLE** To Do
a. Dress yourself, including tying shoelaces and doing buttons?	❑ (0)	❑ (1)	❑ (2)	❑ (3)
b. Get in and out of bed?	❑ (0)	❑ (1)	❑ (2)	❑ (3)
c. Lift a full cup or glass to your mouth?	❑ (0)	❑ (1)	❑ (2)	❑ (3)
d. Walk outdoors on flat ground?	❑ (0)	❑ (1)	❑ (2)	❑ (3)
e. Wash and dry your entire body?	❑ (0)	❑ (1)	❑ (2)	❑ (3)
f. Bend down and pick up clothing from the floor?	❑ (0)	❑ (1)	❑ (2)	❑ (3)
g. Turn faucets on and off?	❑ (0)	❑ (1)	❑ (2)	❑ (3)
h. Get in and out of a car, bus, train, or airplane?	❑ (0)	❑ (1)	❑ (2)	❑ (3)
i. Walk two miles?	❑ (0)	❑ (1)	❑ (2)	❑ (3)
j. Participate in sports and games as you would like?	❑ (0)	❑ (1)	❑ (2)	❑ (3)

CASE 3: Angie Vita

90 year old female with advanced dementia and previous diagnosis of rheumatoid arthritis

- methotrexate 25 mg PO weekly,
  Adalimumab 40 mg SC q2 weekly
  (since she moved into nursing home 5 years ago)
- she has ulnar deviation at the MCP joints, boutonnierre deformities, reduced wrist extension bilaterally
- She does not appear to be in pain when you examine the joints in her hands, and no swelling noted
- X-rays show multiple erosions and wrist ankylosis, but unchanged compared to 2 years ago



WHAT DO YOU DO WITH HER MEDICATIONS?

CASE 3: Angie Vita

90 year old female with advanced dementia and previous diagnosis of rheumatoid arthritis

- methotrexate 25 mg PO weekly,
  Adalimumab 40 mg SC q2 weekly
  (since she moved into nursing home 5 years ago)
- she has ulnar deviation at the MCP joints, boutonnierre deformities, reduced wrist extension bilaterally
- She does not appear to be in pain when you examine the joints in her hands, and no swelling noted
- X-rays show multiple erosions and wrist ankylosis, but unchanged compared to 2 years ago



WHAT DO YOU DO WITH HER MEDICATIONS?

Previous damage is not an indication to immunosuppress. She likely has burnt out RA.

↓MTX 12.5 mg PO weekly x 3 months, then stop. Reassess in 3 months.

↓Humira 40 mg SC q1 month x 3 months, then stop.

REMISSION RATES

- With appropriate treatment 40-60% achieve remission within 1-2 years of diagnosis
- Should we stop therapy if in remission?

  Lancet Oct 2021, 300 patients 6 months remission

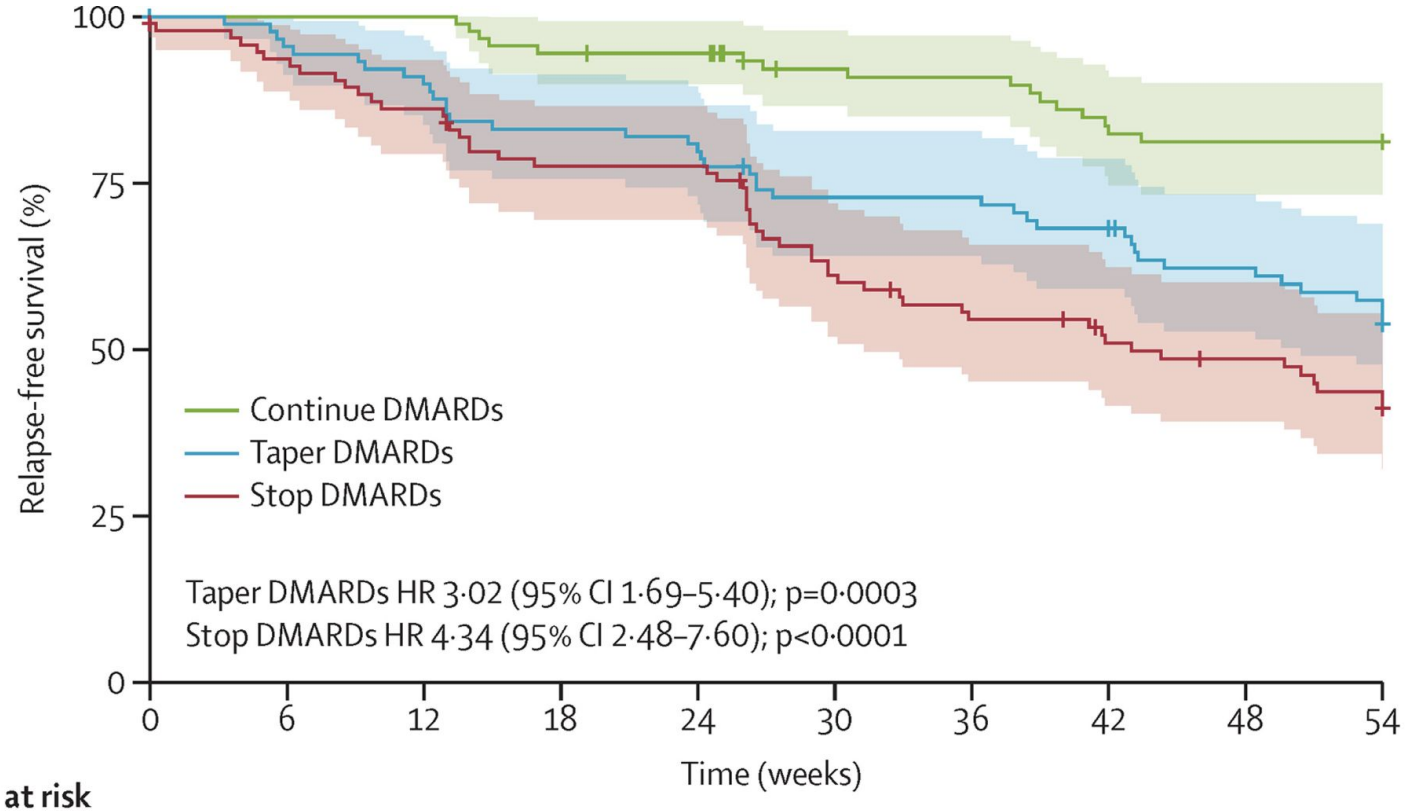

Number at risk (number censored)										
Continue DMARDs	93 (2)	91 (2)	91 (2)	86 (2)	85 (3)	76 (10)	75 (10)	69 (10)	67 (10)	67 (77)
Taper DMARDs	93 (4)	85 (4)	81 (4)	74 (4)	72 (4)	63 (6)	63 (6)	59 (7)	52 (8)	48 (53)
Stop DMARDs	96 (2)	88 (2)	81 (2)	72 (3)	72 (3)	56 (4)	49 (5)	43 (8)	40 (9)	36 (43)

STOPPING MEDICATION?

ACR 2021 Treatment Guidelines

- Individualize → consider dose reduction in after 1 year of remission if disease was relatively easy to treat

Table 5. Tapering disease-modifying antirheumatic drugs (DMARDs)*

Recommendations	Certainty of evidence	Based on the evidence report(s) of the following PICO(s)	Evidence table(s), in Supp. App. 2
Continuation of all DMARDs at their current dose is **conditionally** recommended over a dose reduction of a DMARD.	Low	PICO 54.a	p. 381
Dose reduction is **conditionally** recommended over gradual discontinuation of a DMARD.	Low	PICO 52.C2 and PICO 53. C2	p. 351–5, p. 372–6
Gradual discontinuation is **conditionally** recommended over abrupt discontinuation of a DMARD.	Low	PICO 52.C1 and PICO 53.C1	p. 351, 372
Gradual discontinuation of sulfasalazine is **conditionally** recommended over gradual discontinuation of hydroxychloroquine for patients taking triple therapy who wish to discontinue a DMARD.	Very low	PICO 58	p. 400
Gradual discontinuation of methotrexate is **conditionally** recommended over gradual discontinuation of the bDMARD or tsDMARD for patients taking methotrexate plus a bDMARD or tsDMARD who wish to discontinue a DMARD.	Very low	PICO 59.C1	p. 401

* PICO = population, intervention, comparator, and outcomes; Supp. App. 2 = Supplementary Appendix 2, available on the *Arthritis Care & Research* website at http://onlinelibrary.wiley.com/doi/10.1002/acr.24596/abstract; bDMARD = biologic DMARD; tsDMARD = targeted synthetic DMARD.

COMPLICATIONS

- May shorten lifespan by 5-10 years
- Risk factor for osteoporosis
  - may increase absolute risk by 5-15% on FRAX calculator (excluding steroid use)
- 2x cardiovascular risk
- 2-3x malignancy risk (lymphoma, lung, melanoma)
- 5x infection risk, partly due to medications
- Inducing remission prevents atlanto-axial subluxation, vasculitis, ILD

BONE HEALTH

CASE 4: Angie Vita (continued)

90 year old female with advanced dementia and previous diagnosis of rheumatoid arthritis

- You have now weaned her off methotrexate/Humira
- Bedbound, total care at baseline for other reasons
- She rolls out of bed one night and fractures her hip
- She is admitted to hospital, returns post-op
- No prior bone density on file

DO YOU START TREATMENT FOR OSTEOPOROSIS?



CASE 4: Angie Vita (continued)

90 year old female with advanced dementia and previous diagnosis of rheumatoid arthritis

- You have now weaned her off methotrexate/Humira
- Bedbound, total care at baseline for other reasons
- She rolls out of bed one night and fractures her hip
- She is admitted to hospital, returns post-op
- No prior bone density on file



DO YOU START TREATMENT FOR OSTEOPOROSIS?

Yes, LTC residents with prior fracture of hip is automatically considered high risk

OSTEOPOROSIS

Table 1 – WHO criteria for DXA diagnosis of osteoporosis

Classification	Score
Normal	BMD within 1 SD of young normal adult, T-score –1.0 or higher
Low bone mass, or osteopenia	BMD between 1 and 2.5 SD lower than that of young normal adult, T-score between –1.0 and –2.5
Osteoporosis	BMD more than 2.5 SD lower than that of young normal adult, T-score –2.5 or lower

WHO, World Health Organization; DXA, dual-energy x-ray absorptiometry; BMD, bone mineral density; SD, standard deviation.

OSTEOPOROSIS

Table 1 – WHO criteria for DXA diagnosis of osteoporosis

Classification	Score
Normal	BMD within 1 SD of young normal adult, T-score –1.0 or higher
Low bone mass, or osteopenia	BMD between 1 and 2.5 SD lower than that of young normal adult, T-score between –1.0 and –2.5
Osteoporosis	BMD more than 2.5 SD lower than that of young normal adult, T-score –2.5 or lower

WHO, World Health Organization; DXA, dual-energy x-ray absorptiometry; BMD, bone mineral density; SD, standard deviation.

What if DEXA not available?

HIGH RISK - INDEPENDENT OF DEXA

- FRAX 10 year risk >20% major osteoporotic fracture or >3% hip fracture
  - DEXA not required to perform calculation
- Per CAROC, individuals with a fragility fracture of a vertebra or hip and those with more than one fragility fracture are at high risk of an additional fracture.
- Residents in long term care with any of the following:
  - Prior fracture of hip or spine
  - More than 1 prior fracture (excluding hands, feet)
  - Recent sure of systemic steroids + 1 prior fracture
  - receiving osteoporosis medications before admission to LTC

HIGH RISK - INDEPENDENT OF DEXA

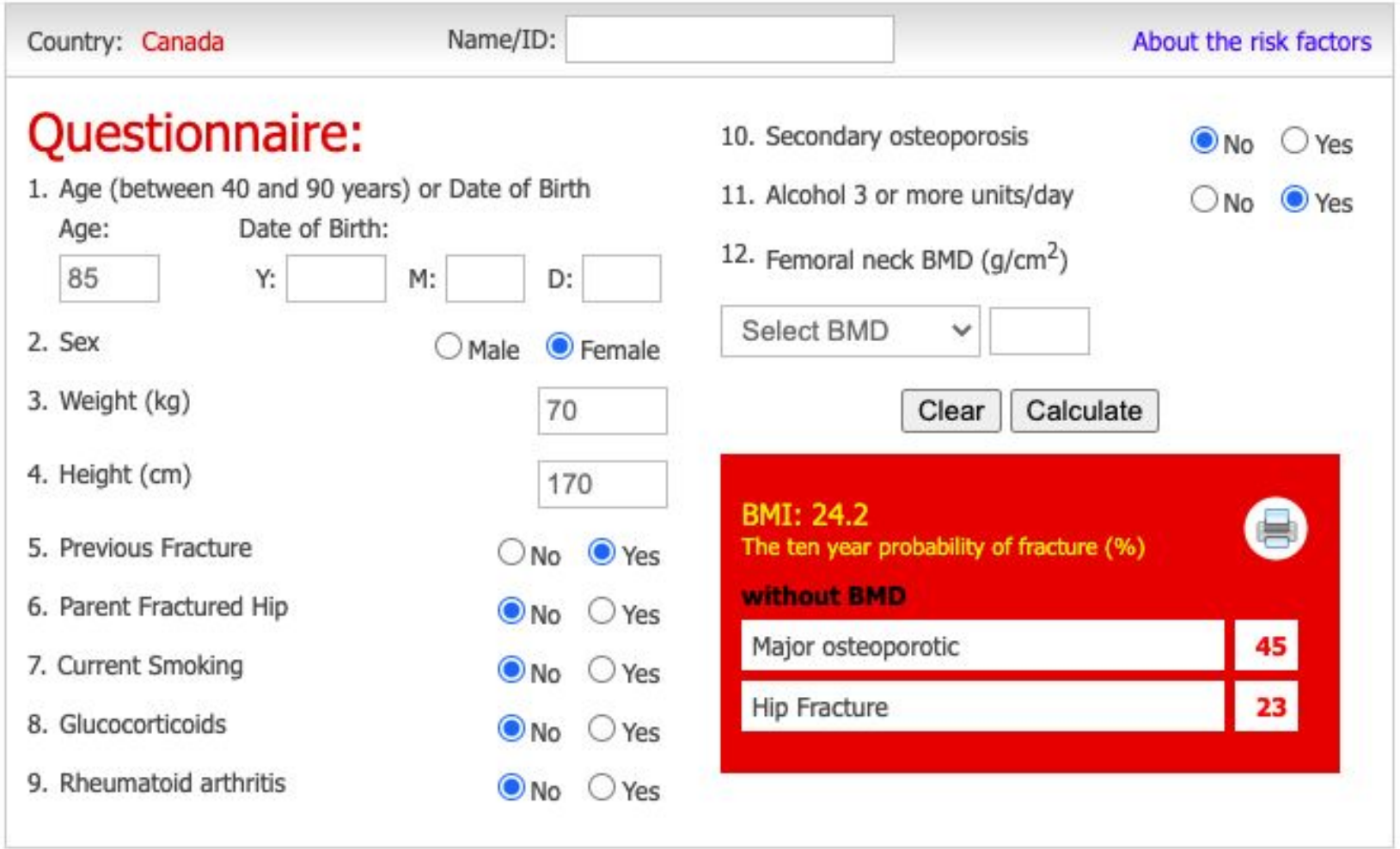

BASELINE ASSESSMENT

RATIONAL CLINICAL EXAMINATION SERIES: DOES THIS WOMAN HAVE OSTEOPOROSIS?

	LR+	LR−
History		
Self-reported humped back	3.0	0.85
Physical		
Weight <51 kg	7.3	0.8
Kyphosis	3.1	0.8
Tooth count <20	3.4	0.8
Rib–pelvis distance ≤2 finger breadths (indicative of spinal fracture)	3.8	0.6
Wall–occiput distance >0 cm (indicative of spinal fracture)	4.6	0.5

- Bloodwork:
  - Calcium/albumin
  - Phosphate
  - 25-hydroxyvitamin D
  - Creatinine
  - ALP
  - TSH
  - SPEP
  - IgA/anti-TTG
- Thoracolumbar spine

MANAGEMENT OPTIONS FOR HIGH RISK LTC RESIDENTS

- Calcium supplementation up to 500 mg daily if cannot meet dietary requirements
- Vitamin D 800-2000 IU daily for everyone
- Hip protectors if mobile
- Multifactorial program - exercise, med review, environmental hazards, assistive device, urinary incontinence

- Start pharmacotherapy if life expectancy >1 year
- First line
  - Alendronate weekly
  - risedronate weekly/monthly
  - zoledronic acid if cannot take PO
  - denosumab if cannot take PO (ok in renal impairment if CrCl >15 ml/min)
- Second line: teriparitide, *romozosumab
- Not recommended: etidronate, raloxifene

DRUG HOLIDAY



- Risk of atypical femoral fractures with prolonged treatment
  - 1/100,000 after 2 years
  - 1/20,000 after 8 years
  - Monitor for anterior thigh pain → XR femur to look for beaking
- Consider drug holiday for oral bisphosphonates after 5 years, iv bisphosphonate after 3 years
- If very high risk:
  - extend oral bisphosphonates up to 8 years and iv bisphosphonate up to 5 years
  - switch to teriparatide for up to 2 years, then resume bisphosphonate therapy
  - switch to denosumab for up to 5 years (risk of AFF but lower)

QUESTIONS?

